

# PARTIAL CLOSURE OF THE LARGEST (EVER MADE) SECUNDUM ATRIAL SEPTAL DEFECT USING A FENESTRATED OCCLUTECH FIGULLA FLEX II® ASD 48mm DEVICE IN A PATIENT WITH NEAR SYSTEMIC PULMONARY ARTERY PRESSURE. CASE REPORT.

Ammar Rasha <sup>1</sup> , Onorato Eustaquio <sup>2</sup> , Akpinar Hakan <sup>3</sup> 



<sup>1</sup>Assistant Professor of Pediatrics, Pediatric Cardiology, Cairo University, Cairo, Egypt

<sup>2</sup>Consultant, Invasive Cardiology Unit, Clinica Montevegino di Mercogliano (Avellino) and Cardiovascular Department, Humanitas Gavazzeni, Bergamo, Italy. Teaching Professor, Interventional Cardiology, Policlinico Universitario Tor Vergata, University School of Medicine, Roma, Italy.

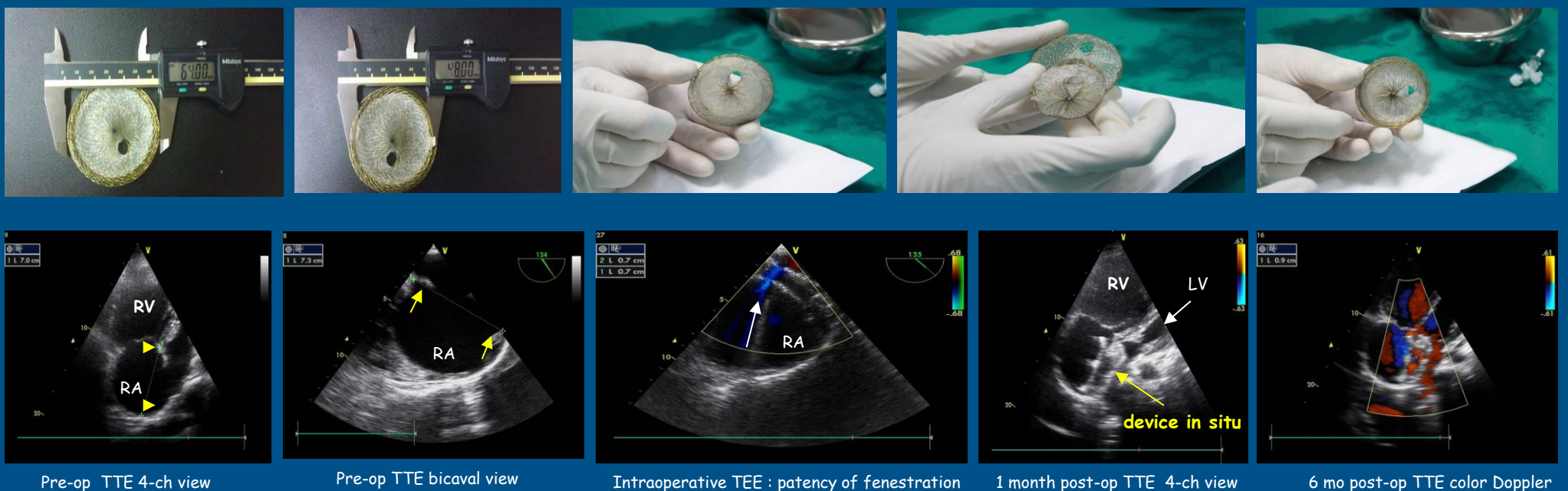
<sup>3</sup>Occlutech International, Chief Technical Officer, Istanbul, Turkey

**Background :** Partial closure has been reported for ASD closure in the elderly and in cases of severe Pulmonary Hypertension (PHTN); with variable results. Some case reports describe different techniques of creating the fenestration. We report the 10 months post operative follow up data of a 36-year-old female with severe PHTN in whom partial closure was successfully achieved using a manufactured fenestrated ASD Occlutech Flex II ® occluder.

**Method and Results:** Successful partial closure of a Large ASD secundum measuring 39 mm was obtained using a custom made fenestrated Occlutech Flex II ® ASD occluder device. The waist measured 48mm and left atrial disc (LA) disc 64mm, with a paracentral fenestration of 8mm. Preload reduction 2 months prior to closure was achieved and heparin for the 1st week, followed by aspirin for 1 year. Daily TTE follow up for the first 2 weeks followed by weekly and then monthly till 12months post-procedure.

At 10 months follow up the fenestration is still patent. Pulmonary artery pressure (PAP) dropped from 90 mmHg to 53 mmHg, right ventricular diastolic dimensions (RVEDD) decreased and left ventricular end diastolic dimensions (LVEDD) increased. NYHA functional class improved from IV to II in 10 months. No device malfunction or thrombus formation was detected

## Fenestrated Occlutech Figulla Flex II® ASD Device 48 mm



**Conclusions :** Management of large secundum ASD and severe PHTN has proven to be challenging. Partial closure using a custom made fenestrated device is a safe and feasible treatment option to reduce the magnitude of the shunt and RV overload. Long term follow up is imperative to plan second stage closure of the fenestration.