

## O-7

### THE OCCLUTECH FIGULLA® ASD OCCLUDER N IN A MULTICENTER, PROSPECTIVE TRIAL: INVESTIGATION OF SAFETY, EFFICACY AND FEASIBILITY

Florian Krizanic<sup>1</sup>, Horst Sievert<sup>2</sup>, Dietrich Pfeiffer<sup>3</sup>, Thomas Konorza<sup>4</sup>, Jaroslav Wojcik<sup>5</sup>, Thomas Comberg<sup>6</sup>, Harald Mudra<sup>7</sup>, Markus Ferrari<sup>1</sup>, Ziyad M. Hijazi<sup>8</sup>, Hans-Reiner Figulla<sup>1</sup>, <sup>1</sup>Clinic of Internal Medicine I, University Hospital, Germany, <sup>2</sup>Cardiovascular Center, Germany, <sup>3</sup>Department of Cardiology, University Hospital, Germany, <sup>4</sup>Heart Center, Germany, <sup>5</sup>Department of Cardiology, University Hospital, Poland, <sup>6</sup>Heart Center, Germany, <sup>7</sup>Department of Cardiology, Clinic Neuperlach, Germany, <sup>8</sup>Section of Pediatric Cardiology Rush University Medical Center, United States

**Background:** The percutaneous closure of secundum atrial septal defect (ASD) is a safe and efficient therapy as compared to surgical intervention. It was our aim to investigate safety, efficacy and feasibility of a novel device system in a clinical prospective trial.

**Methods:** The ASD occluder consists of two retention discs with only one right atrial hub and is available in sizes from 6-40 mm (in 3 mm gradations). Indications for closure included a secundum ASD with a maximum defect diameter of 39 mm,  $Q_p:Q_s > 1,5$  and an absence of Eisenmenger syndrome. Percutaneous closure of secundum ASD was attempted in 20 patients (mean age 48 years). A clinical and diagnostic follow up examination was performed by means of TTE (after 30, 180 days) and TEE after 60 days.

**Results:** Successful implantation was achieved in all patients (n=20/20; mean X-ray exposure time 13,5 min) with no periinterventional complications. One patient with known CHD, heart failure (NYHA IV, EF 35%) and concomitant ASD II died of recurrent myocardial infarction without evidence of cardioembolic origin nine days after implantation according to autopsy study. Complete closure was achieved in 94,7% (n=18/19) sixty days after implantation and in all patients after 180 days follow up. A minimal right-to-left shunt during Valsalva maneuver was determined in 5,3% (n=1/19) after 30 days by TTE and in 5,3% (n=1/19) after 60 days by TEE. 180 days after implantation no residual shunt was observed.

**Conclusions:** The novel Occlutech Figulla® ASD device appears to be easy to use, efficient and feasible for percutaneous closure of secundum ASD.

## O-8

### THE OCCLUTECH FIGULLA® PFO OCCLUDER N IN A SINGLE CENTER, PROSPECTIVE TRIAL: INVESTIGATION OF SAFETY, FEASIBILITY AND USEFULNESS

Florian Krizanic<sup>1</sup>, Markus Ferrari<sup>1</sup>, Hans-Reiner Figulla<sup>1</sup>, <sup>1</sup>Clinic of Internal Medicine I, Germany

**Aims:** We investigated the safety, feasibility and usefulness for closure of patent foramen ovale (PFO) with the innovative nitinol meshwork device (Occlutech Figulla® PFO Occluder N - single layer and double layer) in a single center, prospective trial.

**Methods:** The retention discs of the device (23/25mm; 27/30mm) are connected by a 3 mm waist in the center with only one right atrial side hub. The left atrial disc is produced either with a single or double flat layer, covered by a PET patch, which allows a significant reduction of meshwork material. Indications for closure of PFO included cryptogenic stroke with evidence of a PFO in TEE (max. PFO diameter of 15 mm). The device was implanted in 54 patients with PFO (n=20 with single layer occluder; n=34 with left double layer occluder; mean age 53 years, 18-80 y) by means of fluoroscopy, TEE and ICE. A follow-up examination was performed after 1, 2 and 6 months (TTE day 30 and 180; TEE day 60).

**Results:** Successful implantation was achieved in all patients (mean X-ray exposure time 11,2 min; mean PFO diameter 9,6 mm) with no peri-interventional complications (n=47/54 finished 30 days FU; n=35/54 60 days FU respectively). Complete closure was achieved in 94,3% (n=33/35) and two patients had a minimal residual shunt (n=2/35) after 60 days follow up. Post interventional examination showed no device embolization or thrombus formation.

**Conclusion:** Percutaneous closure of PFO in symptomatic patients by Occlutech Figulla® device represents an effective therapy with

no periinterventional complications and low rates of residual shunt.

## O-9

### ASSESSMENT OF LEFT ATRIAL APPENDAGE EJECTION FRACTION IN THREE DIMENSIONS WITH 64 SLICE COMPUTED TOMOGRAPHY

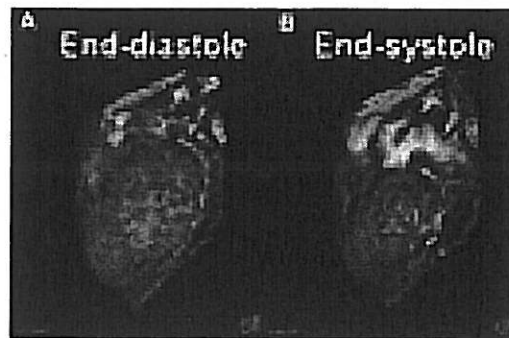
Hidehiko Hara<sup>1</sup>, John Lesser<sup>2</sup>, Robert Schwartz<sup>2</sup>, <sup>1</sup>Toho University Medical Center Ohashi Hospital, Japan, <sup>2</sup>Minneapolis Heart Institute and Foundation, United States

Left atrial appendage (LAA) is a major source of all cardiac emboli, and the function is related with thrombus formation. However, there is no study clearly demonstrated LAA ejection fraction (LAAEF) because of its complex appearance. We assessed the LAAEF in 3 dimensions, and compared with the LAA filling on contrast media using multislice computed tomography (MSCT).

**Methods:** Twenty patients were scanned using MSCT (Somatom Sensation-64, Siemens) using standard contrast media because of their cardiac assessment (57.3±10.6 years, 14 were male). These data were transferred to commercial workstation (Vitrea2, Vital Images Inc), and end-diastolic volumes (EDV), end-systolic volumes (ESV) were measured and LAAEFs were calculated. To evaluate the relationship between LAAEF and LAA filling, CT density at LAA orifice, apex, ascending and descending aorta were measured among patients.

**Results:** LAAEFs were successfully measured by MSCT (Figure A, B). Average LAAEF was measured as 48±15 % (13-70%). There was a significant negative correlation between LAAEF and the difference of CT density (LAA orifice - LAA apex) ( $r^2=.21$ ,  $p=.04$ ). Moreover, a significant inverse correlation between LAA orifice - LAA apex and ascending aorta ( $r^2=.23$ ,  $p=.03$ ), and descending aorta ( $r^2=.38$ ,  $p=.004$ ) were found.

**Conclusions:** LAAEF is capable to be measured by MSCT which provides EDV and ESV in 3 dimensions. LAAEF is proportional to LAA filling demonstrated as the difference of CT density among LAA orifice and apex. These findings suggest that LAAEF measured by non-invasive MSCT could be used for assessment of LAA function which would predict thromboembolic events among patients with cardiovascular diseases.



## O-10

### PERCUTANEOUS PULMONARY VALVE REPLACEMENT USING THE EDWARDS SAPIEN™ TRANSCATHETER HEART VALVE (THV)

Robert Boone<sup>1</sup>, John Webb<sup>1</sup>, Eric Horlick<sup>2</sup>, Qi-Ling Cao<sup>3</sup>, Marla Kiess<sup>1</sup>, Najaf Nadeem<sup>1</sup>, Ziyad Hijazi<sup>3</sup>, <sup>1</sup>St. Paul's Hospital, Canada, <sup>2</sup>Toronto General Hospital, Canada, <sup>3</sup>Rush University Medical Center, United States