

## MEMBER LOGIN

User Name:

Password:

Remember Pass

ENTER

## INTRODUCING TSC

## MEMBERSHIP

## TURKISH BOARD OF CARDIOLOGY

## OFFICIAL JOURNAL

## TSC NATIONAL CONGRESS

## INTERNATIONAL CONGRESS

## CONTACT FORM

Turkish Society of Cardiology  
Headquarters  
Darulaceze Cd. Fulya Sk.  
Eksioğlu Is Merkezi, No:9/1  
Okmeydanı 34384, İstanbul-  
Turkey

Tel +90 (212) 221 17 30  
+90 (212) 221 17 38

Fax +90 (212) 221 17 54



Copyright Notice

Download Fulltext

Correspondence

Türkçe

Türk Kardiyol Dern Arş 2010; 38:189-193

&lt; Volume: 38 Issue: 3

April 2010

## The efficiency and safety of percutaneous closure of secundum atrial septal defects with the Occlutech Figulla device: Initial clinical experience

Erdoğan İlkay, M.D., Fehmi Kaçmaz, M.D., \* Özcan Özeke, M.D., Raşan Sarper Turan, M.D., Sakine Fırat, M.D., Kutluk Pampal, M.D.,# Esra Özer, M.D.,# Selçuk Bilgin, M.D.#

**Objectives:** We evaluated the efficiency and safety of the Occlutech Figulla device in percutaneous closure of secundum atrial septal defects (ASD).

**Study design:** The study included 28 patients (17 women, 11 men; mean age 43 years) who underwent percutaneous transcatheter closure using the Occlutech Figulla device for secundum ASDs causing a hemodynamically significant shunt. Defect size was estimated by transthoracic (TTE) and transesophageal (TEE) echocardiography, and also by balloon sizing in nine patients. The patients were followed-up for six months and were examined by TTE.

**Results:** The mean defect size was 20.3±2.1 mm on TTE, 22.1±1.9 mm on TEE, and 24.2±2.4 mm on balloon sizing. The mean device size was 26.8±3.6 mm (range 6 to 36 mm). The mean procedure time was 44.7±21.4 minutes. The device was placed successfully in all the patients. A small residual flow was seen immediately after device placement in three patients (10.7%), which disappeared in two patients at three months, and in one patient at six months. During the procedure, complications were seen in four patients (14.3%), including transient sinus tachycardia in three patients (10.7%) and acute atrial fibrillation in one patient (3.6%). At six months, all the patients were asymptomatic. No ischemic stroke, cardiac perforation, device erosion, embolization, thrombus formation, or malposition of the device were observed.

**Conclusion:** The Occlutech Figulla occluder is a safe and efficient device to close secundum ASDs. It may be preferred especially in patients with a high risk for thrombus formation.

**Key words:** Echocardiography; heart catheterization; heart septal defects, atrial/therapy; prosthesis design.

**Received:** July 21, 2009 **Accepted:** October 22, 2009 **Correspondence:** Dr. Erdoğan İlkay, Mesa Hastanesi, Kardiyoloji Kliniği, 06510 Ankara, Turkey. Tel: +90 312 - 292 99 57 e-mail: ilkayerdogan@superonline.com

Atrial septal defect (ASD) is the most common congenital heart disease in adults after bicuspid aortic valve.[1] Although patients with ASD often remain asymptomatic until early adulthood, they can present at any age with a variety of clinical symptoms including right ventricular failure, pulmonary hypertension, atrial arrhythmias, and paradoxical embolism.

Since the first transvenous ASD closure was performed by King and Mills in 1974,[2] a number of transcatheter closure devices have been designed and tested in clinical studies.[3-6] Today, with advances in percutaneous device technology, percutaneous closure has proved to be a safe technique to close ASDs.[2,7,8] Among many closure devices, only two were approved by the FDA in 2001 and 2006, respectively, namely the Amplatzer septal occluder (ASO) and the Gore HELEX septal occluder.

The Occlutech Figulla (Occlutech GmbH., Jena, Germany) is a new occluder that has been designed to close secundum ASDs. The major advantage of this occluder is the absence of the left atrial microcrew, which minimizes the chance for clot formation on the left atrial disc. In the present study, we evaluated the efficiency and safety of the Occlutech Figulla device in patients with a secundum ASD.

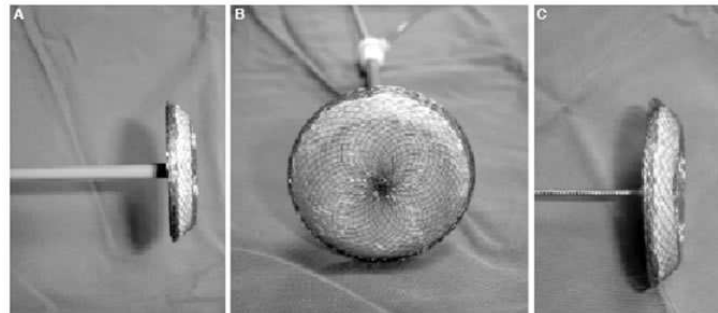


Figure 1. (A) The Figulla Occlutech occluder consists of two flat discs with a 4-mm connecting waist. (B) The left atrial disc without a microcrew hub. (C) The microcrew adapter located in the center of the right atrial disc.

### PATIENTS AND METHODS

**Patients.** The study included 28 patients (17 women, 11 men; mean age 43±28 years) who underwent percutaneous transcatheter closure using the Occlutech Figulla occluder for secundum ASD between January 2007 and February 2008. Patients with a hemodynamically significant shunt ratio (Qp:Qs >1.5:1) were offered elective closure soon after

the diagnosis was established, irrespective of age. The shunt ratio was determined by using oxygen saturations during right heart catheterization and noninvasive flow assessment on transthoracic echocardiography (TTE) examination. Patients with primum or sinus venosus ASD, left ventricular dysfunction, or severe pulmonary artery hypertension were excluded from the study. Severe pulmonary artery hypertension was considered when peak pulmonary artery pressure exceeded 70% of systemic systolic blood pressure. All subjects gave informed consent for participation. The study protocol was performed with approval of local ethics committee and conformed to the Declaration of Helsinki.

**Echocardiography.** All patients underwent TTE to determine the type of ASD and shunt ratio. After a secundum ASD was established, defect size and interatrial septal rims including anteroinferior, posterosuperior, aortic, and superior rims were measured by transesophageal echocardiography (TEE). Percutaneous transcatheter closure was not performed if the length of one of the rims (except anterosuperior rim) was less than 5 mm.

**The device.** The Occlutech Figulla occluder is made up of 0.082-0.186 mm nitinol wires that are tightly woven into two flat discs with a 4-mm connecting waist (Fig. 1a). The device diameter, i.e., the diameter of the waist, is available in varying sizes ranging from 6 to 40 mm, with 1.5-mm increments up to 12 mm, 3-mm increments up to 36 mm, and a 4-mm increment thereafter. The left and right atrial discs are 12 to 16 mm and 8 to 10 mm larger than the diameter of the connecting waist, respectively. The most important characteristics of this new device are the absence of the left atrial disc microscrew (Fig. 1b) which decreases the chance for clot formation on the left atrial disc and increased flexibility due to movement ability of the device. It contains only one stainless steel hub at the right atrial disc for wire connection (Fig. 1c). The size of the delivery sheath varies from 9 to 12 Fr for device diameters 6 to 27 mm (14 Fr for diameters of 30-40 mm).

**Technique.** Percutaneous transcatheter closure was performed under TTE or TEE guidance and premedication with unfractionated heparin with a dose of 100 U per kilogram. After placement of the right femoral vein sheath, a guide wire was positioned into the upper left pulmonary vein through the septal defect and a balloon catheter was inserted under TTE or TEE monitoring. The diameter of the balloon was increased gradually until the Doppler flow disappeared in the defect area. The stretched balloon diameter (SBD) was measured under fluoroscopy when the balloon occluded the defect completely. Although this method has been accepted as the gold standard method in selection of device size, it is not necessary in all ASD patients.[9-11] In our study, balloon sizing was used in the first nine patients (32%) especially in patients having a floppy septum. The SBD of the ASD reflects the diameter of the firm rim margins of the defect. The device was placed using the standard technique. The position and stability of the device were checked by the Minnesota maneuver. The procedure was repeated when the device could not be placed properly or when it was placed completely in the left or right atrium. Finally, the device was released from the carrier system.

In general practice, a closure device 1-2 mm larger than the SBD is chosen for implantation. Slight oversizing generally does not result in procedural or postprocedural complications because closure devices tend to adapt to the geometric anatomy of the interatrial septum over time. Furthermore, slight oversizing may also obviate the need to use a larger device in case of insufficient initial defect closure.[12] In our study, the size of the device was 2-3 mm larger than the SBD or defect diameter estimated by TEE.

All patients were discharged on treatment with 100-300 mg aspirin and 75 mg clopidogrel daily. Prophylaxis for infective endocarditis was recommended during the first six months. At follow-up, all patients were examined by TTE to evaluate residual shunt, the position and stability of the device, and its relationship with adjacent anatomic structures.

## RESULTS

**Defect and device sizes.** The measurement of defect size was made by TTE or TEE, and it was repeated during the procedure. All patients had a single hole in the interatrial septum. The mean defect size was measured as 20.3±2.1 mm on TTE examination, 22.1±1.9 mm (range 4.2-28 mm) on TEE examination, and the mean SBD was 24.2±2.4 mm. The mean defect size was larger on SBD due to compression and stretching of the atrial septum. The mean device size was 26.8±3.6 mm (range 6 to 36 mm).

**Device placement.** To guide the device placement during closure, TTE and TEE were used in five patients and 23 patients, respectively. The mean procedure time was 44.7±21.4 minutes. During TEE monitoring, the repair was performed under general anesthesia in three patients and sedation was used in 20 patients with a dose of 2 mg midazolam and bolus dose of 1 mg/kg propofol. If required, propofol was repeated with a bolus dose of 20 mg.

The device was placed successfully in all the patients and no case of embolization was recorded. A small central residual flow was seen immediately after device placement in three patients (10.7%), which disappeared in two patients at the end of three months, and persisted as a hemodynamically insignificant tiny flow in one patient until six-month examination.

**Complications.** Complications were seen in four patients (14.3%), but none affected the procedural success. Acute atrial fibrillation developed in a 48-year-old woman (3.6%) whose large defect (26 mm) was closed with a 30-mm occluder. Atrial fibrillation resolved and sinus rhythm was obtained after an intravenous single dose of 5 mg metoprolol. Transient sinus tachycardia was recorded in three patients (10.7%) during the procedure, but it recovered to normal rhythm spontaneously in all.

**Follow-up.** All patients were evaluated by TTE during the follow-up. At six months, no residual flow was found and all the patients were asymptomatic. No ischemic stroke, cardiac perforation, device erosion, or embolization were observed during the follow-up. The position of the device remained stable on TTE examination in all the patients.

## DISCUSSION

The Occlutech Figulla occluder is a safe and efficient device to close secundum ASDs. Immediate-, short-, and mid-term clinical results and success rates are comparable with those obtained by the ASO device reported in previous studies.[7,8]

The ASO is the most widely used device worldwide and its excellent results in pediatric and adult patients have been demonstrated in several studies.[13-16] The Gore HELEX septal occluder, on the other hand, has been approved by the FDA to close defects up to 18 mm stretched diameter.[17] The Occlutech Figulla has been designed to close the whole range of defects for which percutaneous closure is indicated. Although it looks similar to the ASO, there are two main differences between the two devices. The ASO consists of a nitinol wire tube that is clamped in two stainless steel hubs on each side of the discs, whereas nitinol wires on the Occlutech Figulla device are braided to avoid a distal clamp,

which offers potential benefits to decrease the chance of clot formation on the left atrial disc and to increase flexibility of the disc for better adaptation in the interatrial septum.

There are several reports on defect closure with the Occlutech Figulla occluder. Krecki et al.[18] used this new device successfully in a patient with patent foramen ovale and history of embolic stroke. Halabi and Hijazi[17] used 12 and 15 mm devices to close multiple ASDs in a child and concluded that this device could be used to close multiple defects with good results. The first clinical results regarding the use of the Occlutech Figulla occluder were reported by Krizanac et al.[19] in 36 patients undergoing percutaneous closure for patent foramen ovale. The authors did not observe thrombus formation on the left atrial disc during the follow-up, possibly due to the absence of a stainless steel hub. Similarly, after percutaneous closure of ASDs, no thrombus was recorded in our study group during the follow-up period.

The rate of residual shunt was reported as 11.8% for the first-generation Occlutech Figulla devices.[19] In the present study, the incidence of residual shunt was 10.7%, which was comparable with the rates associated with the ASO use in large series. Çeliker et al.[20] reported the immediate residual shunt rate as 43.8% in a group of 80 children undergoing percutaneous closure of ASDs, of which two patients (2.5%) had trivial shut during the follow-up period. Despite high rates of immediate residual shunts reported with the ASO device, subsequent residual shunts usually do not have hemodynamic significance and mostly disappear spontaneously within a year follow-up.[13,16,21]

Procedure-related complications including transient ischemic attacks, atrioventricular block, atrial arrhythmias, thrombosis, cardiac perforation, and pulmonary thromboembolism are usually associated with transcatheter closure of large defects and large device use.[22-25] In our study, only atrial tachyarrhythmias (atrial fibrillation in one and sinus tachycardia in three patients) were observed.

Thrombus formation is an important complication that causes severe adverse results and is often seen on the left atrial side. The type of the device and amount of material in the left atrium are the most common risk factors for thrombus formation. The risk is lower with the ASO device compared with other devices such as CardioSEAL, StarFLEX, and PFO-Star.[12,26] Kaya et al.[27] reported no thrombus formation or serious complications in 12 patients undergoing percutaneous transcatheter septal closure of ASDs using the ASO device during a follow-up period of 11.6±2.3 months. We believe that the risk for thrombus formation is lower in the Occlutech Figulla device due to the lesser amount of material on the left atrial side. However, there is still need for randomized studies comparing the two devices with respect to thrombus formation or other complications.

**Study limitations.** In the present study, we just evaluated the clinical use and safety of the Occlutech Figulla device in a small study group. Thus, comparative data with other devices are not provided. Another limitation is that the long-term (>3 years) results evaluating late complications (device erosion) have not been obtained yet.

In conclusion, the Occlutech Figulla occluder is a safe and effective device to close a wide range of defects, with a potentially lower thrombus risk due to lesser material on the left atrial side, rendering it more flexible for adaptation in the interatrial septum.

## REFERENCES

1. McMahon CJ, Feltes TF, Fraley JK, Bricker JT, Grifka RG, Tortoriello TA, et al. Natural history of growth of secundum atrial septal defects and implications for transcatheter closure. *Heart* 2002;87:256-9.
2. King TD, Thompson SL, Steiner C, Mills NL. Secundum atrial septal defect. Nonoperative closure during cardiac catheterization. *JAMA* 1976;235:2506-9.
3. Prieto LR, Foreman CK, Cheatham JP, Latson LA. Intermediate-term outcome of transcatheter secundum atrial septal defect closure using the Bard Clamshell Septal Umbrella. *Am J Cardiol* 1996;78:1310-2.
4. Rao PS, Berger F, Rey C, Haddad J, Meier B, Walsh KP, et al. Results of transvenous occlusion of secundum atrial septal defects with the fourth generation buttoned device: comparison with first, second and third generation devices. International Buttoned Device Trial Group. *J Am Coll Cardiol* 2000;36:583-92.
5. Rickers C, Hamm C, Stern H, Hofmann T, Franzen O, Schröder R, et al. Percutaneous closure of secundum atrial septal defect with a new self centering device ("angel wings"). *Heart* 1998;80:517-21.
6. Rome JJ, Keane JF, Perry SB, Spevak PJ, Lock JE. Double-umbrella closure of atrial defects. Initial clinical applications. *Circulation* 1990;82:751-8.
7. Sommer RJ, Hijazi ZM, Rhodes JF Jr. Pathophysiology of congenital heart disease in the adult: part I: Shunt lesions. *Circulation* 2008;117:1090-9.
8. Samánek M. Children with congenital heart disease: probability of natural survival. *Pediatr Cardiol* 1992; 13:152-8.
9. Amin Z, Daufors DA. Balloon sizing is not necessary for closure of secundum atrial septal defects. [Abstract] *J Am Coll Cardiol*. 2005;45(suppl 1):317.
10. Zanchetta M. On-line intracardiac echocardiography alone for Amplatzer Septal Occluder selection and device deployment in adult patients with atrial septal defect. *Int J Cardiol* 2004;95:61-8.
11. Wang JK, Tsai SK, Lin SM, Chiu SN, Lin MT, Wu MH. Transcatheter closure of atrial septal defect without balloon sizing. *Catheter Cardiovasc Interv* 2008;71:214-21.
12. Kim MS, Klein AJ, Carroll JD. Transcatheter closure of intracardiac defects in adults. *J Interv Cardiol* 2007;20:524-45.
13. Du ZD, Hijazi ZM, Kleinman CS, Silverman NH, Larntz K; Amplatzer Investigators. Comparison between transcatheter and surgical closure of secundum atrial septal defect in children and adults: results of a multicenter nonrandomized trial. *J Am Coll Cardiol* 2002;39:1836-44.
14. Patel A, Lopez K, Banerjee A, Joseph A, Cao QL, Hijazi ZM. Transcatheter closure of atrial septal defects in adults > or =40 years of age: immediate and follow-up results. *J Interv Cardiol* 2007;20:82-8.
15. Spies C, Timmermanns I, Schröder R. Transcatheter closure of secundum atrial septal defects in adults with the Amplatzer septal occluder: intermediate and long-term results. *Clin Res Cardiol* 2007;96:340-6.
16. Masura J, Gavora P, Podnar T. Long-term outcome of transcatheter secundum-type atrial septal defect closure using Amplatzer septal occluders. *J Am Coll Cardiol* 2005;45:505-7.
17. Halabi A, Hijazi ZM. A new device to close secundum atrial septal defects: first clinical use to close multiple defects in a child. *Catheter Cardiovasc Interv* 2008;71:853-6.
18. Krecki R, Peruga JZ, Plewka M, Krzemińska-Pakuła M, Kasprzak JD. Implantation of a Occlutech Figulla PFO occluder in a patient with patent foramen ovale and history of embolic stroke. *Cardiol J* 2008;15:380-2.
19. Krizanac F, Sievert H, Pfeiffer D, Konorza T, Ferrari M, Figulla HR. Clinical evaluation of a novel occluder device (Occlutech) for percutaneous transcatheter closure of patent foramen ovale (PFO). *Clin Res Cardiol* 2008;97:872-7.
20. Çeliker A, Özkutlu S, Karagöz T, Ayabakan C, Bilgiç A. Transcatheter closure of interatrial communications with Amplatzer device: results, unfulfilled attempts and special considerations in children and adolescents. *Anadolu Kardiyol Derg* 2005;5:159-64.

21. Wang JK, Tsai SK, Wu MH, Lin MT, Lue HC. Short- and intermediate-term results of transcatheter closure of atrial septal defect with the Amplatzer septal occluder. *Am Heart J* 2004;148:511-7.
22. Suda K, Raboisson MJ, Piette E, Dahdah NS, Miró J. Reversible atrioventricular block associated with closure of atrial septal defects using the Amplatzer device. *J Am Coll Cardiol* 2004;43:1677-82.
23. Chessa M, Carminati M, Butera G, Bini RM, Drago M, Rosti L, et al. Early and late complications associated with transcatheter occlusion of secundum atrial septal defect. *J Am Coll Cardiol* 2002;39:1061-5.
24. Levi DS, Moore JW. Embolization and retrieval of the Amplatzer septal occluder. *Catheter Cardiovasc Interv* 2004;61:543-7.
25. Amin Z, Hijazi ZM, Bass JL, Cheatham JP, Hellenbrand WE, Kleinman CS. Erosion of Amplatzer septal occluder device after closure of secundum atrial septal defects: review of registry of complications and recommendations to minimize future risk. *Catheter Cardiovasc Interv* 2004;63:496-502.
26. Krumsdorf U, Ostermayer S, Billinger K, Trepels T, Zadan E, Horvath K, et al. Incidence and clinical course of thrombus formation on atrial septal defect and patent foramen ovale closure devices in 1,000 consecutive patients. *J Am Coll Cardiol* 2004;43:302-9.
27. Kaya MG, Özdođru İ, Baykan A, Dođan A, İnanç T, Dođdu O, et al. Transcatheter closure of secundum atrial septal defects using the Amplatzer septal occluder in adult patients: our first clinical experiences. [Article in Turkish] *Türk Kardiyol Dern Arş* 2008;36:287-93.

2011 © All rights reserved. Turkish Society of Cardiology.

[LookUs & Online Makale](#)