



ONE -YEAR FOLLOW DATA AFTER SUCCESSFUL PARTIAL CLOSURE OF A LARGE ASD WITH SEVERE PULMONARY HYPERTENSION USING CUSTOM MADE OCCLUTECH-FLEX II® DEVICE

Ammar Rasha ¹ , Onorato Eustaquio ² , Akpınar Hakan ³ 



¹Assistant Professor of Pediatrics, Pediatric Cardiology, Cairo University, Cairo, Egypt

²Consultant, Invasive Cardiology Unit, Clinica Montevergine di Mercogliano (Avellino) and Cardiovascular Department, Humanitas Gavazzeni, Bergamo, Italy. Teaching Professor, Interventional Cardiology, Policlinico Universitario Tor Vergata, University School of Medicine, Roma, Italy.

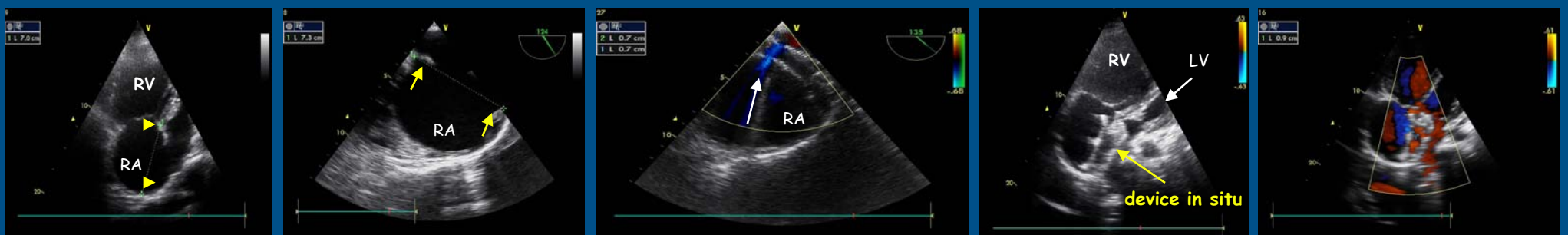
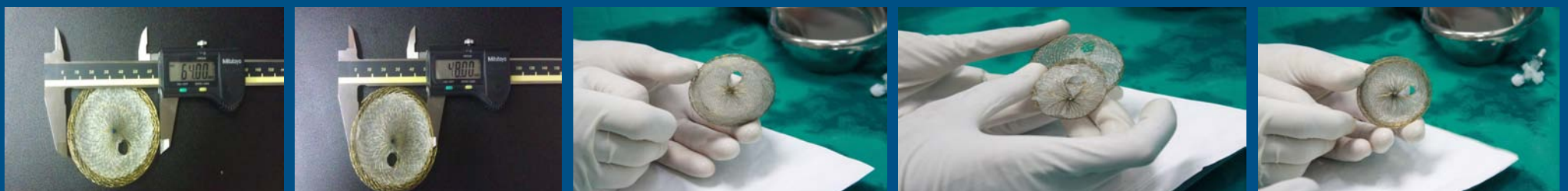³Occlutech International, Chief Technical Officer, Istanbul, Turkey

Background : Partial closure has been reported for ASD closure in the elderly and in cases of severe Pulmonary Hypertension (PHTN) with variable results. Some case reports describe different techniques of creating the fenestration. We report the one - year post operative follow up data of a 36-year-old female with severe PHTN in whom partial closure was successfully achieved using a manufactured fenestrated Occlutech Figulla® Flex II ASD occluder.

Method and Results: Successful partial closure of a large ASD secundum measuring 39mm using a manufacturer made fenestrated device Occlutech Figulla® Flex II ASD occluder. The waist measured 48mm and left atrial (LA) disc 64mm, with a fenestration of 8mm. Preload reduction 2 months prior to closure was achieved and heparin for the 1st week, followed by aspirin for 1 year were given. Daily TTE follow up was performed for the first 2 weeks followed by weekly and then monthly till 12months post-procedure.

At 12months follow up the fenestration is still patent. Pulmonary artery pressure (PAP) dropped from 90 mmHg to 53 mmHg, right ventricular diastolic dimensions (RVEDD) decreased and left ventricular end diastolic dimensions (LVEDD) increased. NYHA functional class improved from IV to II in one year. No device malfunction or thrombus formation was detected.

Fenestrated Occlutech Figulla Flex II ASD Device 48 mm



Pre-op TTE bicaval view

Intraoperative TEE : patency of fenestration

1 month post-op TTE 4-ch view

1 mo post-op TTE color Doppler

Conclusions : Partial closure is safe and succeeds in reducing the magnitude of the shunt when using a custom made fenestrated device. Long term follow up is crucial to plan total closure of the defect