

Initial Experience of Atrial Septal Defect Closure with Occlutech Figulla Device at Queen Alia Heart Institute

Awni Madani., MD, Majdi Jaafreh., MD, AbdelFatah Haweleh., MD, Issa Hijazi.,MD, Ali Obedat.,MD, Yaser Goul.,MD, Mohammad Mrawah, MD,Raed Amlih.,RN, Fakhri Hakim., MD

Abstract

Objective:

To evaluate the effectiveness of the Occlutech Figulla occluder device in the treatment of ostium secundum atrial septal defect .

Methods:

This is a retrospective cohort study conducted between June 2008-June 2011 involving 54 cases with ostium secundum atrial septal defect who underwent transcatheter closure using the Occlutech Figulla device. All procedures were done under general anesthesia with continuous transesophageal echocardiographic monitoring. Clinical and echocardiographic assessment were done after 24 hours and then after 1, 3 and 6 months respectively. The results are presented as means, standard deviations and percentages.

Results:

From the 54 cases 33 patients (61%) were females. Their mean age and weight were 16.47 ± 11.8 year, 38.4 ± 20.7 Kg respectively. The mean atrial septal defect diameter by transesophageal echocardiogram was 13.2 ± 4.2 mm , and the mean atrial septal defect size of the implanted device was 15.97 ± 4.5 mm , ranging from 10.5 to 27mm. Two cases were sent for surgery due to inadequate postero-inferior rim .The procedure success rate was 96.3%. In 5 cases (9.6%) there were trivial residual shunt after 24 hours of the procedure which were disappeared at follow up.

Conclusion: The Occlutech device is safe and effective for transcatheter closure of secundum atrial septal defect . We need a long term follow up studies to evaluate the safety of the device.

Key words: Atrial septal defect , Occlutech Figulla , Transcatheter closure.

Abbreviations:

ASD: Atrial septal defect

ASO: Amplatzer Septal Occluder

TEE: Trans-Esophageal Echocardiogram

**Correspondence to: Dr. Awni Madani.,MD, FSCAI, FACC. JBP
Senior Consultant Interventional Pediatric Cardiologist
Chief of Pediatric Cardiology Department –
Queen Alia Heart Institute- Royal Medical Services - Amman-Jordan.
P.O.Box 6372 E-mail: amadani33@hotmail.com**

Introduction:

Atrial septal defects (ASDs) are one of the most common cardiac congenital defects, accounting for 5-10% of all cases. It predominates in females with 1.5-3.5:1 female/male ratio (1). Ostium secundum ASD accounts for 75% of this pathology and the remaining 25% are due to ostium primum ASD, sinus venosus ASD and coronary sinus ASD (2). Since 1948, when Murray described the first atrioseptoplasty (3), it has been the gold standard surgical therapy offering excellent immediate results. Transcatheter closure using a device has become an alternative treatment strategy for a patient with an appropriate size secundum atrial septal defect (ASD). Until recently, the most widely used device was the Amplatzer Septal Occluder (ASO). Other devices *were* used also include the Helex device (WL Gore), CardioSeal/Starflex (NMT Medical) and the Intrasept (Cardia Medical). Subsequently clinical studies have been demonstrating that the results with these devices are similar to surgery (4-5). It has been often reported in medical literature that deficient rims are intimately related to the failure of the procedure and inadequate attachment of the device to the septum (7-8). The Occlutech Figulla device (Occlutech GmbH., Jena, Germany) is a new recently approved and is being used with increasing frequency to close secundum ASDs (6). The objective of this study is to evaluate the effectiveness of the Occlutech Figulla device for transcatheter closure of ASD at Queen Alia Heart Institute in Amman – Jordan

Methods:

A written informed consent was obtained from the patients or their parents or their guardians one day prior to the procedure, and the study was approved by the local Royal Medical Services ethical committee. 2D -TEE was performed in every patient during the procedure. Then clinical examination, ECG and echocardiogram were done after 1, 3, and 6 months, and then were followed up regularly on an annual basis

Study population- From June 2008 - June 2011, 54 patients underwent percutaneous closure of ostium secundum ASD. Thirty three patients were female (61%), their mean age and weight were 16.47 ± 11.8 year, 38.4 ± 20.7 Kg respectively, and the

range of follow up period between 6 months and 3 years. All the patients underwent regular follow up.

Inclusion criteria for ASD closure.

An ASD with a pulmonary- to-systemic flow ratio ($Q_p:Q_s$) $>1.5:1$, right heart volume overload and development of symptoms.

Exclusion criteria for ASD closure.

The exclusion criteria for ASD closure were: reversal right-to-left shunt, a shunt volume ($Q_p:Q_s < 1.5:1$), pulmonary vascular resistance >7 Wood Units/ m^2 , defect diameter >36 mm, acute infection, presence of concomitant other types of ASD such as primum or sinus venosus, and presence of intracardiac thrombi .

Statistical analysis – The results are expressed as means , standard deviations and percentages.

The Device: The Occlutech Figulla device Fig.1 (Occlutech GmbH., Jena, Germany) is constructed from 0.082 to 0.186 mm Nitinol wires, tightly woven into two flat disks with a connecting waist (Fig.1). The device diameter is indicated by the diameter of the waist and is available in sizes ranging from 6-40mm with a 3mm increment, except from size 6-12 in 1.5 mm increments and in 4 mm increment from 36-40mm Table I. The prosthesis is filled (left and right disc and the connecting waist) with a polyester patch to enhance thrombogenicity. There is only one stainless steel hub (microscrew) at the right atrial disc for cable connection (Fig.1a,b). The delivery sheath required ranges in size from 9 to 14 Fr (devices size 6-9mm require 9 Fr; devices size 12& 15 mm require 10Fr; devices 18-27 mm require 12 Fr; and devices size 30-40mm require 14 Fr. The most unique features of this device are the absence of the left atrial stainless steel hub and the ability to reposition the device after deployment of the left and right atrial discs, before device release .

Transcatheter procedure:

The procedures were performed in the catheterization laboratory under general anesthesia and TEE monitoring . During catheterization , right and left cavity pressures were recorded , blood samples were taken for oximetry and to calculate the Qp/Qs ratio and pulmonary vascular resistance. The size of the device was determined using the actual transesophageal echocardiogram (TEE) measurement (Fig.2 a,b) of the ASD and by adding 25% to this size of the defect . We also examined the relationship of the device with adjacent structures, such as the atrioventricular valves, the pulmonary veins, the superior and inferior vena cava , and the coronary sinus .

The right femoral vein was punctured under local anesthesia and a soft-tipped 0.065 inch wire was inserted and advanced through the atrial defect, and finally positioned within a left-sided pulmonary vein . Intravenous heparin (100 IU/Kg) was administered to keep the activated clotting time (ACT) 200 seconds .Next, an appropriate delivery sheath was advanced to the left atrial side over the guidewire. The Occluder was subsequently located in a Cook Delivery sheath (*Cook, INC., Bloomington, Indiana*) and advanced by means of the delivery system to the left atrial disc, the system was retracted until the left atrial disc was positioned opposite the left interatrial septum . The right atrial disc was deployed thereafter. Before device release, the cable was pushed forward and backward ("Minnesota Wiggle"). Correct positioning was confirmed by means of fluoroscopy and Trans-Esophageal Echocardiography(TEE) . When the occluder was positioned properly, it was released by opening the microscrew anticlockwise. Also TEE was used to check the shape of the device , the possibility of thrombus formation either on or around the device , and the presence of residual or additional defects (Fig.3)

Follow-up protocol after 24 hours:

Prior to discharge at 24 hours, they underwent a chest X-ray , ECG and echocardiographic examinations. The patients received Aspirin 5mg/Kg for 6 months until full endothelialization of the device and were advised to take antibiotic prophylaxis to prevent infective endocarditis for six months .

Results:

Between June 2008 and June 2011 , 54 patients with mean age 16.4 ± 11.8 year and weight of 38.4 ± 20.7 Kg . Thirty three patients were females (61%) and 21 patients (39%) were males. The mean ASD diameter measured by TEE was 13.2 ± 4.2 mm and the mean size of the device used was 15.9 ± 4.5 mm. The procedure success rate 96.3% . Two cases were sent for elective cardiac surgery due to deficient postero-inferior rim .

Periprocedural complications:

Residual shunt after 24 hours of the procedure was present in 5 patients (9.6%) which *were* disappeared at follow up .There were no major complications during the procedure (death, device embolization or need for immediate cardiac surgery). There were minor complications in 7 patients(13.4 %), 3 patients (5.7%) had bleeding at the puncture site, 2 patients (3.8 %) had transient ST elevation in the inferior leads which was probably due to air embolization *was* resolved spontaneously within 5 minutes and 2 patients(3.8%) had premature atrial contractions which lasted for about 10 to 15 minutes.

Follow up :

During the transthoracic echocardiogram study we checked the position of the device, particularly in relation to the tricuspid valve, the superior and inferior venae cavae, the pulmonary veins, and the coronary sinus. We looked for a possible residual shunt, thrombus formation on or around the device, as well as possible deformation of the device. During the follow-up period between 6 months to 3 years, no *patients* had *any*

major complications (cardiac rupture, device embolization, thrombus formation, thromboembolism or infective endocarditis.

Discussion

Although surgical mortality and morbidity of ASD closure are minimal (7), percutaneous closure of ASD secundum has become an attractive therapeutic alternative due to comparable success rates combined with even lower morbidity rates and shorter hospital stays (8,9). Even though this study was a cohort with a small number of patients, it demonstrates that occlusion of ASD secundum using the Occlutech Figulla device is safe and effective, and we can say that it can be an alternative to surgical treatment for selected patients. An important and essential aspect is the TEE monitoring during the procedure. This guidance offers adequate visualization of the rims of the defect and safe deployment of the device as well as confirmation that the vital structures such as vena cavae, coronary sinus are not compressed. If the device is deployed without this critical evaluation the chance of incomplete defect occlusion or embolization of the prosthesis increase significantly. Besides the device's proven safety, the transcatheter procedure avoids midsternotomy, aortic clamping and extracorporeal circulation. In addition to other surgical complications and longer hospital stay. The procedure presents a low rate (13.4%) of minor hospital complications, reduced hospital stay and safety, which is comparable with the midterm follow up of other studies (9,10). From the 52 cases included in the study, there were no deaths, cardiac perforations or other serious complications during the hospital phase, which is consistent with other reports (6,11). During the follow up period from 6 months-to 3 years there were also no cases of thrombi, embolization or endocarditis related to the device have been recorded.

Immediate, short and mid-term clinical results and success rates are comparable with those obtained by the (ASO)device which are reported in previous studies(12-13). There are several reports on defect closure with the Occlutech Figulla device(11,14). Krechiet et al (14) used this new device successfully in a patient with patent foramen ovale and history of embolic stroke. Embolization of the device or device components, or device dislodgement or misplacement, has been observed with most devices (15-

18), we didn't have any embolization in our cohort study, and we believe that rate of embolization could be reduced with greater operator experience. Formation of thrombus on the device with or without systemic embolization has also been observed with other devices (15-18). Krezanic et al (19,20) reported his first clinical results regarding the use of the Occlutech Figulla device in 36 patients undergoing percutaneous closure for patent foramen ovale. The authors did not observe thrombus formation on the left atrial disc during their follow-up. Similarly, no thrombus was recorded in our study group during the follow-up period.

We, and Halabi et al (6) and Erdogan et al (11) believe that the risk for thrombus formation is lower in the Occlutech Figulla device due to the absence of the left atrial microscrew, which minimizes any chances for clot formation on the left atrial disc. Bacterial endocarditis prophylaxis is important in order to reduce the rate of endocarditis with vegetation formation, as was observed with other devices(10-13,14),also we didn't notice any case with endocarditis in our study. The only minor limiting factor was the size of the sheath required, which usually requires 2 French sizes larger than other devices like the Amplatzer septal occluder (ASO) device. When the device is used in a small child , the small delivery sheath is more helpful , so we believe that we have to address the company in order to reduce the profile of the device in order to allow for implantation via lower profile sheaths. The rate of residual shunt was reported as 11.8% for the first generation Occlutech Figulla devices (7), whereas Erdogan et al(11) found that the residual shunt was 10.7% which is comparable with our study 9.6% and the ASO device used in large series(11,21,22). Despite the immediate presence of residual shunts reported with the ASO and other devices, subsequent residual shunts usually do not have hemodynamic significance and mostly disappear spontaneously within 6 months to one year of follow- up. (11,21,22).

Study limitations: This was an uncontrolled retrospective cohort study , the follow up period is relatively short.

Conclusion:

The Occlutec device is safe and effective for transcatheter closure of ostium secundum ASD with a potentially lower thrombus risk due to lesser material on the left atrial side, rendering it more flexible for adaptation in the interatrial septum.

Appropriate patient selection, as well as accurate device sizing to fit the dimensions of the defect, are important factors for the success and the safety of the procedure. The sheath needed for the device deployment is quite big for small children, so we have to address the company to reduce the profile of the device in order to use lower-profile sheaths. We need a long term follow up studies to evaluate the safety of the device.

Table I. Recommended delivery systems for the Occlutec devices.

Device size	Recommended Delivery sheath	Waist (mm)	LA disc (mm)	RA disc (mm)
6	7 Fr	6	16.5	12.5
7	7 Fr	7.5	18	14
9	7 Fr	9	20.5	16.5
10	7 Fr	10.5	22	18
12	10 Fr	12	27	23
15	10 Fr	15	30	26
18	12 Fr	18	33	29
21	12 Fr	21	36	32
24	12 Fr	24	39	35
27	14 Fr	27	42	38
30	14 Fr	30	45	41
33	14 Fr	33	48	43
36	14 Fr	36	52	46
39	14 Fr	39	54	49

Figures:

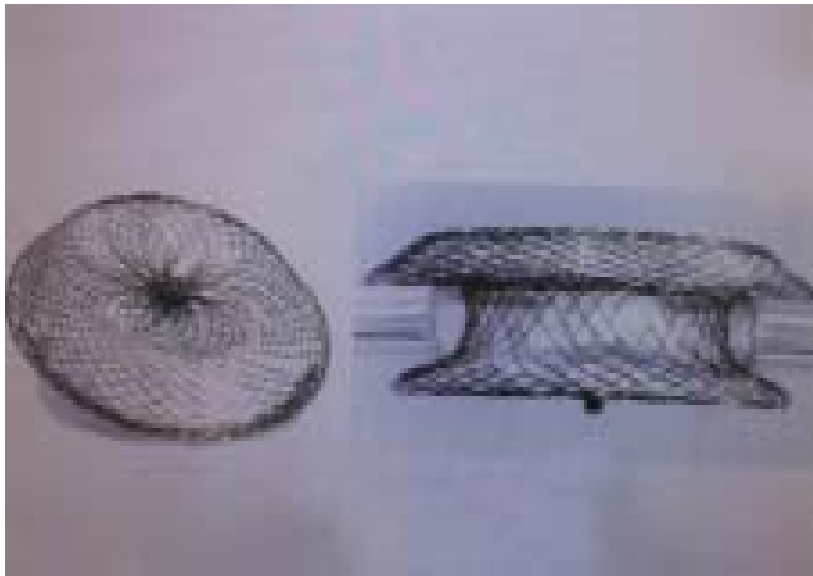


Fig.1a: Occlutech Figulla ASD device.



Fig.1b: The Occlutech Figulla device .The device attached to the delivery cable.
Note the absence of the microscREW in the left atrial disc.

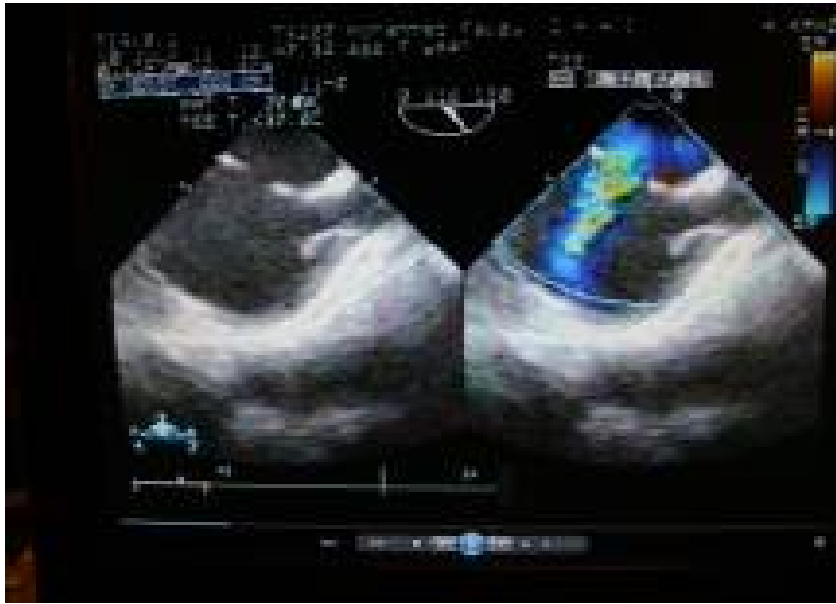

Fig.2.a: Trans-Esophageal Echocardiogram . Bicaval view with and without colour shows the ASD

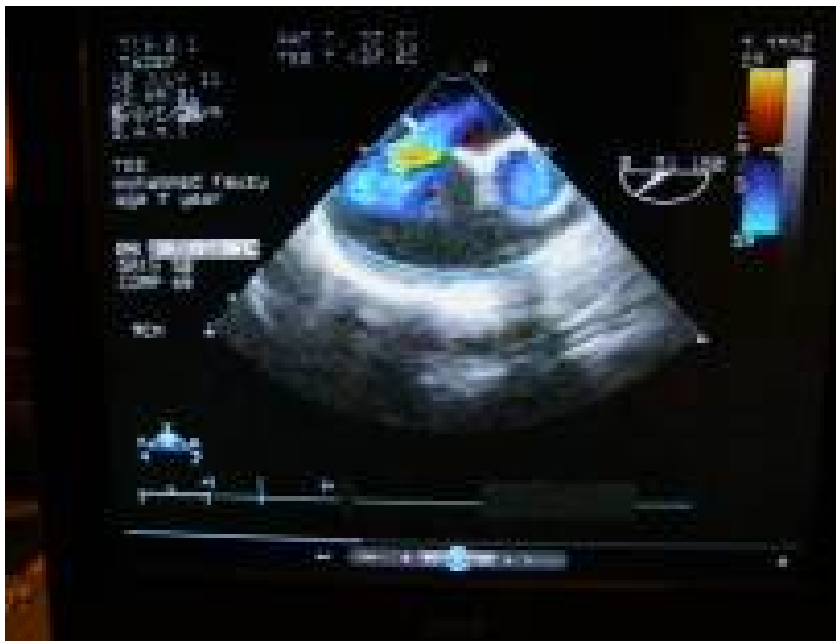

Fig.2.b: Trans-Esophageal Echocardiogram. Coloured short axis view shows the ASD

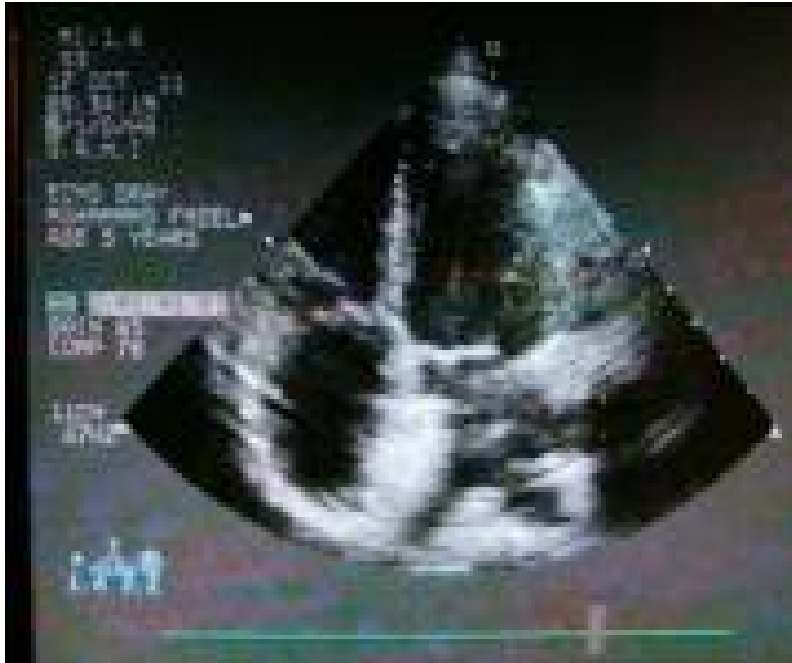

Fig.3: Trans-Esophageal Echocardiogram. Four chamber view shows the device occluding the ASD.

References:

1. Braunwald E, Zipes D, Libby P. Heart Disease.6th ed. Philadelphia: Saunders Company;2001
2. Ho YS ,Baker EJ, Rigby ML, et al .Congenital heart disease, morphologic and clinical correlations: Barcelona:Mosby-Wolfe;1995
3. Murray G. Closure of defects in cardiac septa .Ann Surg.1948;128:843
4. Thomson JD, Aburawi EH, Watterson KG et al .Surgical and transcatheter (Amplatzer) closure of atrial septal defects: a prospective comparison of results and cost. Heart.2002;87:466-469
5. Cowley CG, Lloyd TR, Bove EL et al. Comparison of results of closure of secundum atrial septal defect by surgery versus Amplatzer septal occluder. Am J Cardiol.2001;88:589-591
6. Halabi A, Hijazi ZM. Anew device to close secundum atrial septal defects: first clinical use to close multiple defects in a child. Cathet Cardiovasc Interv 2008;71: 853-856
7. Du ZD, Koenig P, Cao QL, Waight D, Heitschmidt M, Hijazi ZM. Comparison of transcatheter closure of secundum atrial septal defect using the Amplatzer septal occluder associated with deficient versus sufficient rims. Am J Cardiol. 2002;90:865-9.
8. Podnar T, Martanovic P, Gavora P, Masura J. Morphological variations of secundum-type atrial septal defects: feasibility for percutaneous closure using Amplatzer septal occluders. Cathet Cardiovasc Intervent. 2001;53:386-91
9. Yew G, Wilson NJ. Transcatheter atrial septal defect closure with Amplatzer septal occluder: five years follow-up. Cathet Cardiovasc Interv. 2005;64(2):193-10.
10. Masura J, Gavora P, Podnar T. Long-term outcome of transcatheter secundum-type atrial septal defect closure using Amplatzer septal occluders. J Am Coll Cardiol. 2005;45:505-7.
11. Erdogan Ilkay , Fehmi Kacmaz , Ozcan Ozeke , et al .The efficiency and safety of percutaneous closure of secundum atrial septal defects with Occlutech Figulla device: Initial clinical experience. Arch Turk Soc Cardiol 2010;38(3): 189-193
12. King T,Thompson S, Steiner C, ET AL. Secundum atrial septal defect: Nonoperative closure during cardiac catheterization. JAMA 1976;235:2506-2509
- 13 Rashkind W. Transcatheter treatment of congenital heart disease. Circulation 1983;67:711-716
14. Kreckiet R, Peruga JZ, Plewka M et al . Implantation of an Occlutech Figulla PFO occluder in a patient with patent foramen ovale and history of embolic stroke. Cardiol J 2008;15:380-382.
15. Willcoxson FE, Thomson JD, Gibbs JL. Successful treatment of left atrial disk thrombus on an Amplatzer atrial septal defect occluder with abciximab and heparin. Heart 2004;90:e30.
- 16.Chessa M, Carminati M, Butera G et al. Early and late complications associated with transcatheter occlusion of secundum atrial septal defect. J Am Coll Cardiol 2002;39:1061–1065.

- 17. Acar P, Aggoun Y, Abdel-Massih T. Images in cardiology: Thrombus after transcatheter closure of ASD with an Amplatzer septal occluder assessed by three dimensional echocardiographic reconstruction. Heart 2002;88:52.**
- 18. Cetta F, Arruda MJ, Graham LC. Large left atrial thrombus formation despite warfarin therapy after device closure of a patent foramen ovale. Catheter Cardiovasc Interv 2003;59:396–398.**
- 19. Kiraznic F, Sievert H, Pfeiffet D et al . Clinical evaluation of a novel occluder device (Occlutech) for percutaneous transcatheter closure of patent foramen ovale (PFO). Clin Res Cardiol 2008; 97: 872-877**
- 20. Kiraznic F, Sievert H, Pfeiffer D, et al . The Occlutech Figulla PFO and ASD Occluder: A new Nitinol wire mesh device for closure of atrial septal defects. J Invasive Cardiol 2010;22:182-187**
- 21. Thanopoulos BD, Laskari CV, Tsaousis GS, et al. Closure of atrial septal defects with the Amplatzer occlusion device: Preliminary results. J Am Coll Cardiol 1998;31:1110-1116**
- 22. Chan KC, Godman MJ, Walsh K, et al. Transcatheter closure of atrial septal defect and interatrial communications with a new self expanding nitinol double disc (Amplatzer septal occluder): Multicenter UK experience. Heart 1999;82:100-106**