

The Occlutech Figulla PFO and ASD Occluder: A New Nitinol Wire Mesh Device for Closure of Atrial Septal Defects

Florian Krizanic, MD,* Horst Sievert, MD,^{§,**} Dietrich Pfeiffer, MD,[£] Thomas Konorza, MD[¶]
Markus Ferrari, MD,* Ziyad Hijazi, MD,[∞] Christian Jung, MD,* Alexander Lauten, MD*
Hans Reiner Figulla, MD, PhD*

ABSTRACT: Background. We investigated the safety, feasibility and efficacy of the Occlutech® devices for patent foramen ovale (PFO) and atrial septal defect (ASD) closure in a prospective trial. **Methods.** The retention discs of the PFO device (23 x 25 mm, 27 x 30 mm) are connected by a 3 mm waist in the center with only one right atrial side central pin. The left atrial disc is produced either with a single or double flat layer, which allows a significant reduction of meshwork material. The ASD occluder (6–40 mm, 3 mm increments) has only one central pin on the right atrial side. Indications for closure included cryptogenic stroke with evidence of a PFO on transesophageal echocardiography (TEE) or an ASD II. The devices were implanted in 29 patients with PFO and in 12 patients with ASD II (fluoroscopy and TEE). An echocardiographic follow-up examination was performed after 1, 2 and 6 months. **Results.** The devices were successfully implanted in all 41 patients. There were no periprocedural complications. One patient with ASD II died of recurrent myocardial infarction without evidence of cardioembolic origin. TEE studies showed a residual shunt in 11.2% after 60 days in patients with PFO and a left-to-right shunt in 9.1% of the remaining patients with ASD II. After 180 days only 1 patient with PFO had a right-to-left shunt (3.7%). A residual shunt in the patients with ASD was not observed. **Conclusions.** The novel Occlutech devices appear to be safe, feasible and effective for PFO and ASD closure, with a significant reduction of the meshwork and absence of left atrial central pin.

J INVASIVE CARDIOL 2010;22:182–187

Key words: patent foramen ovale, atrial septal defect

A patent foramen ovale (PFO) has been increasingly recognized as a mediator of paradoxical embolism.^{1,2} Several studies using contrast echocardiography established a strong association between PFO and cryptogenic stroke in patients with a

cocombitant atrial septal aneurysm, older age (> 55 years) and more than one previous stroke.^{3–7,24,25}

In stable patients without contraindications for surgical closure a pulmonary-to-systemic flow ratio Qp:Qs > 1.5:1 is widely accepted as an indication for atrial septal defect secundum type (ASD II) closure.²⁶ Smaller ASDs (Qp:Qs < 1.5:1) are closed if paradoxical embolism or volume overload is present.³²

Transcatheter interventional closure of a PFO and ASD II has become a routine procedure for adults and children, with a low risk of periprocedural complications and good long-term findings according to the results in large retrospective studies as compared to alternative therapies.^{21,37,39–43} It was our aim to report the use of this novel device which is characterized by reduction of left atrial material, ease of deployment, retrievability at every stage and high flexibility for PFO and ASD closure up to 40 mm.

Methods

The Occlutech Figulla® PFO Occluder N (left atrial single layer and double layer) (Occlutech GmbH, Jena, Germany). The device, developed using a unique patented braiding technique, consists of a nitinol wire mesh to create a smooth and flexible outer layer. Two retention discs (diameter 23 x 25 mm and 27 x 30 mm) allow for a single central pin on the right atrial side. The discs are connected by a 3 mm waist in the center. Two polyethylene terephthalate (PET) patches assure complete closure after implantation (Figures 1A–D). The device's uniqueness lies in the fact that the left atrial disc consists only of a single layer without a hub, thereby minimizing the amount of material on the left atrial side. The patented self-centering mechanism is incorporated into the device for optimal positioning and repositioning of the device within the defect. An integral locking delivery and retrieval mechanism ensures safe and stable deployments and allows a tilt up to 45°. It avoids any risk of unintended release during handling and allows safe retraction into the catheter. In addition, a double-layer left atrial disc for closure of PFO defects with a long tunnel morphology and ASA is available (Figures 1C and D). The device is characterized by its flexibility, ease of handling, ability to self-center in the shunt and its ease of recapture before disconnection from the delivery system.

The Occlutech Figulla ASD Occluder N. With ASDs, the defect diameter may range from 6 mm to larger than 40 mm in extreme cases. Corresponding waist diameters from 6 mm to 40 mm are available. Typically, the diameter of the left atrial

From the *Clinic of Internal Medicine I, University Hospital Jena, Germany; [§]CardioVascular Center, Frankfurt/M., Germany and **Washington Hospital Center, Washington, D.C.; [£]Department of Cardiology, University of Leipzig, Germany; [¶]Heart Center Essen, Department of Cardiology, University of Essen, Germany; [∞]Rush University Medical Center, Chicago.

Trial Funding: The trial was supported by a grant provided by Occlutech® GmbH, Jena, Germany.

Disclosures: Dr. Florian Krizanic is a consultant for Occlutech and received honoraria for clinical research. Prof. Dr. H.R. Figulla has stock ownership in Occlutech.® The other authors report no conflicts of interest.

Manuscript submitted June 1, 2009, provisional acceptance given July 10, 2009, final version January 12, 2010.

Address for correspondence: Dr.med.univ. Florian Krizanic, Clinic of Internal Medicine I, University Hospital Jena, Germany 07740. E-mail: Florian.Krizanic@med.uni-jena.de

Table 1. Patient demographics.

Age, years	mean 50 ± 14
Male	18
Female	23
Arterial hypertension	19
Insulin-dependent DM	1
Non-insulin-dependent DM	3
Transient ischemic attack	20
Stroke	9
DM = diabetes mellitus	

disc is approximately 14 mm and the right atrial disc is approximately 10 mm larger than the waist. PET patches are arranged within both discs and also within the waist (Figures 2A and B). The size of the occluder to be used depends on the size of the defect. The device size chosen is usually the same, ± 2 mm of the stretched diameter, as this will ensure an optimal fitting of the occluder. This “stop-flow” technique assures the choice of the appropriate device size, but more aggressive balloon sizing is not employed. If the device diameter is overestimated, this can lead to constriction of the waist and to a mushroom-like shape of the occluder.

Patients. In an open, prospective, nonrandomized, multicenter clinical study, investigation of usefulness, feasibility and safety was performed in 41 patients.

Animal experiments. Preclinical animal studies were conducted to evaluate the technical feasibility of the concept,³⁶ which showed that the novel device appears to be comparable to other presently used implantation systems in terms of feasibility and handling. In the animal study, the device was implanted in 10 Goettingen mini pigs. Macroscopic, angiographic and histopathological follow up did not show any superficial thrombus formation, wire fractures or major inflammatory reactions. Nevertheless, a few lymphocytic infiltrations and some foreign giant body cells near the polyester fibers were seen in the implant. The extent of inflammatory reactions was similar to that described for other devices.^{33,35} Overall, good biocompatibility of this novel device was demonstrated.

Inclusion criteria for PFO closure. Indications for closure of PFOs included patients (age 18–80 years) who suffered from cryptogenic stroke with evidence of a PFO in contrast echocardiography (PFO diameter ≤ 15 mm according to sizing balloon).

Inclusion criteria for ASD closure. An ASD with a pulmonary-to-systemic flow ratio (Qp:Qs) > 1.5:1, volume overload or paradoxical embolism was accepted for interventional closure.

Exclusion criteria for PFO closure. The exclusion criteria for PFO closure included the following: atrial fibrillation, significant stenosis of the carotid arteries, known thrombophilic disorders, pregnancy, recent MI, acute infection and allergic reaction to clopidogrel, aspirin and nickel, age < 18 years and PFO diameters ≥ 15 mm by balloon sizing.

Table 2. Patient recruitment and study completion.

Total enrollment	n = 41
Atrial septal defect (ASD)	n = 12
Patent foramen ovale (PFO)	n = 29
Implanted PFO devices, mm	n = 29 with 23 x 25 mm PFO
Implanted ASD devices, mm	n = 3 with ASD 15 mm n = 6 with ASD 18 mm n = 2 with ASD 21 mm n = 1 with ASD 24 mm
Qp:Qs, mean	1 : 1.73 ± 0.39
Successful implantation	41
Device success	41
Discontinuation after implantation	1 (PFO n = 1)
Completed study, day 1	40 (ASD n = 12, PFO n = 28)
Cardiac death within 30 days	1 (ASD n = 1)
Lost to follow up, days 1–180	1 (PFO n = 1)
Completed study, day 30	38
Completed study, day 60	38
Completed study, day 180	38 (ASD n = 11, PFO n = 27)
Defect size mean (PFO), mm	8.5 ± 2.5
Defect size mean (ASD), mm	17.4 ± 4.1

Table 3. Outcome, complications and efficacy related to the type of device used for patent foramen ovale and atrial septal defect closure.

	Occlutech ASD Occluder	Occlutech PFO Occluder
Patients	11	27
Successful implantation	11	27
Periprocedural complication, total	0	0
Cardiac death, not device-related	1	0
Complete closure, efficacy (%)		
Day 60	10 (90.9%)	24 (88.9%)
Day 180	11 (100%)	26 (96.3%)
Recurrence		
Transient ischemic attack	0	0
Stroke	0	0
Other thromboembolic event	0	0
Thrombus formation	0	0
Device dislodgement	0	0
Pericardial effusion	0	0
Arrosion of aorta	0	0
Inguinal hematoma	0	0
Atrial arrhythmia	0	0
ASD = atrial septal defect; PFO = patent foramen ovale		

Exclusion criteria for ASD closure. The exclusion criteria for ASD closure were: reversal right-to-left shunt, a shunt volume (Qp:Qs < 1.5 :1), pulmonary vascular resistance > 7 Wood units, defect diameter > 36 mm, recent myocardial infarction (MI) or operative myocardial revascularization within < 30 days, acute infection, allergic reaction to clopidogrel, aspirin and nickel, presence of concomitant other types of ASD such as primum or sinus venosus, intracardiac thrombi and permanent contraindications to platelet therapy.

Table 4. Recommended delivery systems for the Occlutech devices.

Type	Recommended Delivery System	Ø Waist [mm]	Ø LA Disc [mm]	Ø RA Disc [mm]	PFO Size [mm]	ASD Size [mm]
Flexible (LA single layer) 23/25	9 Fr		23	25	D ≤ 13	
Standard (LA double layer) 16/18 23/25 27/30 31/35	7 Fr 9 Fr 10 Fr 12 Fr		16 23 27 31	18 25 30 35	D ≤ 8 8 < D ≤ 13 13 < D ≤ 15 D ≥ 15	
Standard (LA double layer) 6 7 9 10 12 15 18 21 24 27 30 33 36 39 40	7 Fr 7 Fr 7 Fr 7 Fr 10 Fr 10 Fr 12 Fr 12 Fr 12 Fr 14 Fr 14 Fr 14 Fr 14 Fr 14 Fr 14 Fr	6.0 7.5 9.0 10.5 12.0 15.0 18.0 21.0 24.0 27.0 30.0 33.0 36.0 39.0 40.0	16.5 18 20.5 22 27 30 33 36 39 42 45 48 52 54 55.5	12,5 14 16,5 18 23 26 29 32 35 38 41 43 46 49 50		D ≤ 6 6 < D ≤ 7.5 7.5 < D ≤ 9 9 < D ≤ 10.5 10.5 < D ≤ 12 12 < D ≤ 15 15 < D ≤ 18 18 < D ≤ 21 21 < D ≤ 24 24 < D ≤ 27 27 < D ≤ 30 30 < D ≤ 33 33 < D ≤ 36 36 < D ≤ 39 39 < D ≤ 40

ASD = atrial septal defect; LA = left atrial; RA = right atrial; PFO = patent foramen ovale

Study participation. All patients were referred for closure until the desired number of patients was recruited. The number was determined to obtain CE mark. All patients gave written informed consent. The trial was approved by the local ethical committee and the international ethical committee of Freiburg.

Implantation procedure for PFO and secundum ASD. The right femoral vein was punctured under local anesthesia and a soft-tipped 0.035 inch wire was inserted and advanced through the atrial defect, and finally positioned within a left-sided pulmonary vein (LAO 35°/cranial 35°). Intravenous heparin (100 IU/kg) was administered to keep the activated clotting time (ACT) > 200 seconds. With the help of a compliant sizing balloon (NuMED, Inc., Hopkinton, New York), the size and anatomy of the defect were determined. Next, an appropriate delivery sheath was advanced to the left atrial side over the guidewire (Table 4). The Occluder was subsequently loaded in a short Cook® delivery sheath (Cook, Inc., Bloomington, Indiana) and advanced by means of the delivery system to the left atrial side. After opening the left atrial disc, the system was retracted until the left atrial disc was positioned opposite the left interatrial septum. The right atrial disc was deployed thereafter.

Before device release, the cable was pushed forward and backward (“Minnesota Wiggle”). Correct positioning was confirmed by means of fluoroscopy and transesophageal echocardiography

(TEE). An initial residual right-to-left-sided shunt was ruled out by contrast injection using the side arm of the delivery sheath with pulmonary levophase. Adequate device position was determined by the lack of movement of the device in either direction (LAO 45–50°/cranial 5–15°) (Figure 3). When the occluder was positioned properly, it was released by opening the locking mechanism and advancing the spool (Figure 4).

Medication. Dual platelet inhibition was started with aspirin 100 mg and clopidogrel 75 mg on the previous day and extended for 3 months for clopidogrel and 6 months for aspirin in cases of ASD. For PFOs, lifelong aspirin was recommended. A prophylaxis for the prevention of endocarditis was recommended for 6 months according to the guidelines.

Endpoints of the study. The endpoints of the study were the effectiveness of the PFO device and the efficacy of the ASD devices. The primary endpoint was complete PFO and ASD closure after 6 months assessed by TEE. Secondary endpoints were major complications related to the procedure. *Safety* was defined as the absence of adverse events directly related to the device, procedure and/or antiplatelet medical therapy.

Follow up. On the first day after implantation, all patients underwent fluoroscopic control, electrocardiography and laboratory tests. Follow-up transthoracic echocardiograms (TTEs) were performed after 30, 60 and 180 days. TEE was




Figure 1A. Patent foramen ovale single-layer device with a PET patch on the left atrial surface. The left atrial geometry allows for reduction of metal and minimizes thrombus formation.

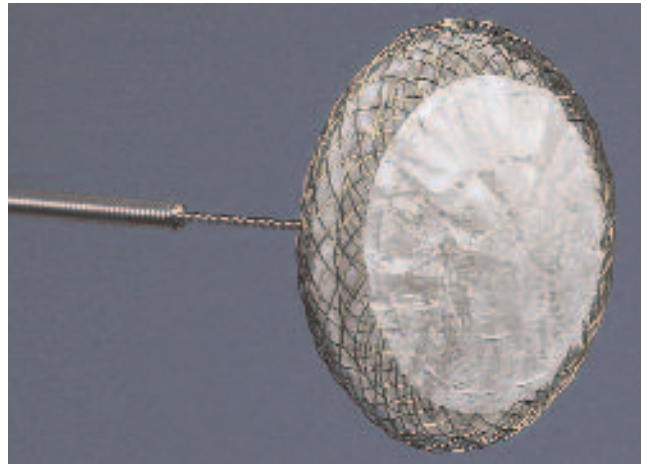


Figure 1B. The braiding technique allows for the absence of a left atrial pin.




Figure 1C. The left atrial double-layer device is characterized by its flexibility which provides adaptation to challenging anatomy. Therefore, sizing flexibility reduces the number of sizes needed in stock.




Figure 1D. Avoiding a distal pin provides sizing flexibility by allowing the strands of the device to move and to adapt to the individual situation.

performed after 60 days to look for thrombus formation and residual shunting. Agitated saline or galactose-based Echovist contrast agent with a Valsalva maneuver were used to determine the quantification of the residual shunt after PFO and ASD device implantation. A “small” shunt volume was defined as 3–20 bubbles and a “large” residual shunt as > 20 bubbles. An atrial septal aneurysm was defined as an interatrial septum of abnormal mobility with septal protrusion in the left or right atrium of at least 10 mm beyond baseline.¹⁵

A Data, Safety, and Adverse Events Monitoring Committee (*HC Management GmbH, Homburg/Saar, Germany*) reviewed and evaluated all reported adverse events.

Results

A total of 41 patients were enrolled in the study between February and July 2007. Details of the patient demographics are listed in Table 1. Table 2 shows patient recruitment for the treatment group. A successful implantation was achieved in all patients ($n = 41/41$). In 1 patient, the study was stopped due to a disagreement to continue examinations after procedure ($n = 1/41$) and another patient was lost to follow up ($n = 1/41$).

One patient with a combination of severe ischemic heart disease (left ventricular ejection fraction of 35%, New York Heart Association Class IV) and a concomitant ASD (diameter 15 mm) died of recurrent MI without evidence of cardioembolic origin 9 days after implantation according to an autopsy study. Autopsy ruled out thrombus formation on the occluder surface. The occluder was in correct position. Macroscopic examination of the heart revealed severe chronic ischemic heart disease with a subacute MI.

Thirty-eight patients completed the 30-, 60- and 180-day follow up. Complete closure was achieved in 88.9% ($n = 24/27$) of the patients with PFOs and in 90.9% ($n = 10/11$) of patients with ASD IIs after 60 days. In 11.1% ($n = 3/27$) of the patients, a minimal residual shunt was detected by TEE after 60 days in patients with PFOs and 9.1% ($n = 1/11$) in patients with ASDs. After 180 days' follow up, there was a mild residual shunt in only 1 patient (3.7%; $n = 1/27$) with a PFO. Additionally a left-to-right-sided shunt was not established in the patients with ASDs. No thrombus formation was seen on the surface of the device. Correct positioning without device dislodgement was observed in all patients. (Tables 2 and 3). There were no postprocedural complications.

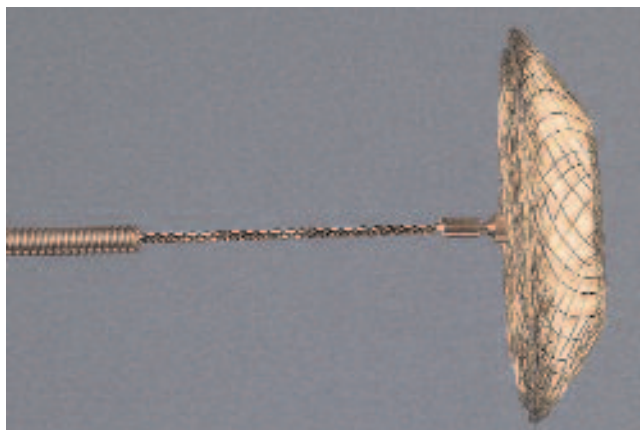


Figure 2A. The atrial septal defect device is available from sizes between 6 mm and 40 mm (in 3 mm increments). Three PET patches assure complete closure after implantation and improve tissue ingrowth.




Figure 2B. The atrial septal defect device is retrievable at any stage of procedure and easy to deploy by its novel delivery system.

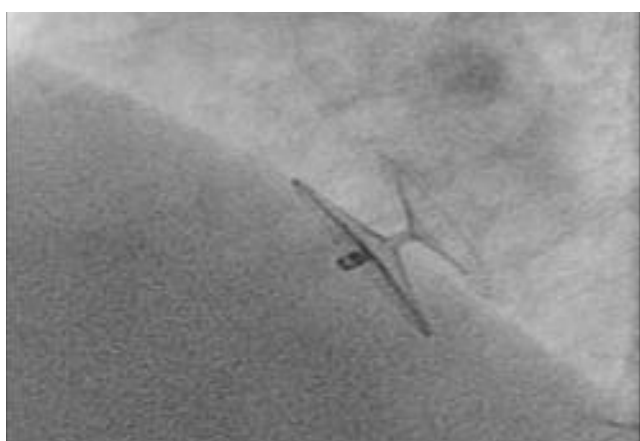

Figure 3. Fluoroscopic view of a patent foramen ovale single disc device (LAO 35°, cranial 7°).

Discussion

Patients with PFOs and paradoxical embolism are also at increased risk for recurrent thromboembolic events, with a combined cerebrovascular accident (CVA) and transient ischemic attack (TIA) rate of 3–8% per year.^{8,9} A large PFO size^{10–12} and presence of an atrial septal aneurysm (ASA)^{13,14}

have been identified as morphological characteristics of PFOs portending a high risk for cryptogenic embolism.

ASD device closure is only available for patients with a defect diameter < 40 mm and with adequate rims to assure secure deployment. Although surgical mortality and morbidity are minimal,¹⁶ percutaneous closure of ASD II has become an attractive therapeutic alternative due to comparable success rates combined with even lower morbidity rates and shorter hospital stays.^{17,18} It is appreciated that a PFO is a frequent cause of cerebral embolism.²² To this day, there is a continuous debate as to how these patients should be treated.^{20–22}

Despite the existence of several different PFO and ASD devices with varying designs, the Occlutech device is characterized by its > 50% reduction of left atrial material in comparison to the Amplatzer® Septal Occluder system (AGA Medical Corp., Plymouth, Minnesota). The major feature of this device is the absence of a left atrial clamp, thus minimizing any chance for trauma and clot formation on the left atrial disc. The devices are available in sizes ranging from 6–40 mm in 1.5 mm increments up to 12 mm, and in 3 mm increments thereafter. Thus, the number of devices that need to be stocked in the catheterization laboratory is only 15, thereby reducing inventory costs. Long-term observations are needed to determine if the geometry of the left atrial disc can reduce thromboembolic complications following interventional PFO closure. Sigler et al showed that protruding metal frame parts, like central pins or spring arms, were covered last.^{33,36} Therefore, it seems possible that these parts carry the risk of thrombus formation on the device surface. The delivery system allows improvements in product handling because of final positioning without any adverse tension.

ASD occlusion in adult patients with advanced age and left or right heart diastolic or systolic heart failure and concomitant pulmonary hypertension bears a considerable risk of worsening heart failure.³⁴ In our patient, complete closure of the ASD might have resulted in progressive left-heart failure and death. Embolization of the device or device components, or device dislodgement or misplacement, has been observed with most devices.^{27–30} The rate could be reduced with greater operator experience. Formation of thrombus on the device with or without systemic embolization has also been observed with the Amplatzer system.^{27–30} However, it is not clear whether this is related to true thrombogenicity. Bacterial endocarditis prophylaxis is important in order to reduce the rate of endocarditis with vegetation formation, as was observed with the Amplatzer Occluder.^{27–30,38} Considerations pertaining to the size of the delivery sheath, ease of implantation, cost and availability are different with each of the devices. The Amplatzer appears to require a smaller delivery sheath, 9–12 Fr, in comparison to the Occlutech system. When the device is used in a young/small child, the small delivery sheath is helpful.

But in older children and adults, the size of the Occlutech delivery sheath, 9–14 Fr, is not a major concern. Actually, Occlutech has taken steps to reduce the profile of the device in order to allow for implantation via lower-profile sheaths. Additionally, Occlutech has ambitious efforts to produce more varying device sizes with regard to the pediatric product selection.



Figure 4. The delivery system allows a tilt of up to 45° giving easy placement prior to release without any tension. The safe-handling attachment system avoids any risk of unintended release and allows safe retraction into the sheath in case of interruption of the procedure.

Conclusion

Use of the Occlutech PFO and ASD devices appears to be safe, feasible, useful and effective for percutaneous ASD and PFO closure. Nevertheless, it is important to note that the data are from a very small patient population. Additional long-term results are needed to confirm the first experience.

References

- Cohnheim J. *Thrombose und Emboli: Vorlesung über allgemeine Pathologie*, Berlin, Germany: Hirschwald; 1877, p.134.
- Thompson T, Evans W. Paradoxical embolism. *QJ Med* 1930;23:135–150.
- Lechat P, Mas JL, Lascault G, et al. Prevalence of patent foramen ovale in patients with stroke. *N Engl J Med* 1988;318:1148–1152.
- Webster MW, Chancellor AM, Smith HJ, et al. Patent foramen ovale in young stroke patients. *Lancet* 1988;2:11–12.
- Hausmann D, Mugge A, Becht I, Daniel WG. Diagnosis of patent foramen ovale by transesophageal echocardiography and association with cerebral and peripheral embolic events. *Am J Cardiol* 1992;70:668–672.
- Di Tullio M, Sacco RL, Gopal A, et al. Patent foramen ovale as a risk factor for cryptogenic stroke. *Ann Intern Med* 1992;117:461–465.
- Cabanes L, Mas JL, Cohen A, et al. Atrial septal aneurysm and patent foramen ovale as risk factors for cryptogenic stroke in patients less than 55 years of age: A study using transesophageal echocardiography. *Stroke* 1993;24:1865–1873.
- Mas JL, Zuber M, French Study Group on Patent Foramen Ovale and Atrial Septal Aneurysm. Recurrent cerebrovascular events in patients with patent foramen ovale, atrial septal aneurysm, or both and cryptogenic stroke or transient ischemic attack. *Am Heart J* 1995;130:1083–1088.
- Bogousslavsky J, Garazi S, Jeanrenaud X, et al, for the Lausanne Stroke with Paradoxical Embolism Study Group. Stroke recurrence in patients with patent foramen ovale: the Lausanne Study. *Neurology* 1996;46:1301–1305.
- Homma S, Di Tullio MR, Sacco RL, et al. Characteristics of patent foramen ovale associated with cryptogenic stroke: A biplane transesophageal echocardiographic study. *Stroke* 1994;25:582–586.
- Hausmann D, Mugge A, Daniel WG. Identification of patent foramen ovale permitting paradoxical embolism. *J Am Coll Cardiol* 1995;26:1030–1038.
- Stone DA, Godard J, Corretti MC, et al. Patent foramen ovale: Association between the degree of shunt by contrast transesophageal echocardiography and the risk of future ischemic neurologic events. *Am Heart J* 1996;131:158–161.
- Mugge A, Daniel WG, Angermann C, et al. Atrial septal aneurysm in adult patients: A multicenter study using transthoracic and transesophageal echocardiography. *Circulation* 1995;91:2785–2792.
- Agmon Y, Khandheira BK, Meissner I, et al. Frequency of atrial septal aneurysms in

- patients with cerebral ischemic events. *Circulation* 1999;99:1942–1944.
- Stone DA, Godard J, Corretti MC, et al. Patent foramen ovale: Association between the degree of shunt by contrast transesophageal echocardiography and the risk of future ischemic neurologic events. *Am Heart J* 1996;131:158–161.
- Craig RJ, Selzer A. Natural history and prognosis of atrial septal defect. *Circulation* 1968;37:805–815.
- Galal MO, Wobst A, Hales Z, et al. Perioperative complications following surgical closure of atrial septal defect type II in 232 patients — A baseline study. *Eur Heart J* 1994;15:1381–1384.
- Berger F, Vogel M, Alexi-Meskishvili V, Lange PE. Comparison of results and complications of surgical and Amplatzer device closure of atrial septal defects. *J Thorac Cardiovasc Surg* 1999;118:674–678, Discussion 678–680.
- Du ZD, Hijazi ZM, Kleinman CS, et al. Comparison between transcatheter and surgical closure of secundum atrial septal defect in children and adults: Results of a multicenter nonrandomized trial. *J Am Coll Cardiol* 2002;39:1836–1844.
- Satler LF. Should PFO closure devices be used “off label.” *Catheter Cardiovasc Interv* 2002;56:527.
- M Braun, V Glicch, A Boscheri, et al. Transcatheter closure of patent foramen ovale (PFO) in patients with paradoxical embolism: Peri-procedural safety and mid-term follow-up results of three different device occluder systems. *Eur Heart J* 2004;25:424–430.
- Windecker S, Wahl A, Chatterjee T, et al. Percutaneous closure of patent foramen ovale in patients with paradoxical embolism: Long-term risk of recurrent thromboembolic events. *Circulation* 2000;101:893–898.
- Chan KC, Godman MJ, Walsh K, et al. Transcatheter closure of atrial septal defect and interatrial communications with a new self expanding nitinol double disc device (Amplatzer septal occluder): Multicentre UK experience. *Heart* 1999;82:300–306.
- Mas JL, Arquizaun C, Lamy C, et al. Patent foramen ovale and atrial septal aneurysm Study Group. Recurrent cerebrovascular events associated with patent foramen ovale, atrial septal aneurysm, or both. *N Engl J Med* 2001;345:1740–1746.
- Handke M, Harloff A, Olschewski M, et al. Patent foramen ovale and cryptogenic stroke in older patients. *N Engl J Med* 2007;357:2262–2268.
- Konstantinides S, Geibel A, Olschewski M, et al. Comparison of surgical and medical therapy for atrial septal defect in adults. *N Engl J Med* 1995;333:469–473.
- Willcoxson FE, Thomson JD, Gibbs JL. Successful treatment of left atrial disk thrombus on an Amplatzer atrial septal defect occluder with abciximab and heparin. *Heart* 2004;90:e30.
- Chessa M, Carminati M, Butera G et al. Early and late complications associated with transcatheter occlusion of secundum atrial septal defect. *J Am Coll Cardiol* 2002;39:1061–1065.
- Acar P, Aggoun Y, Abdel-Massih T. Images in cardiology: Thrombus after transcatheter closure of ASD with an Amplatzer septal occluder assessed by three dimensional echocardiographic reconstruction. *Heart* 2002;88:52.
- Cetta F, Arruda MJ, Graham LC. Large left atrial thrombus formation despite warfarin therapy after device closure of a patent foramen ovale. *Catheter Cardiovasc Interv* 2003;59:396–398.
- Gatzoulis MA, Freeman MA, Siu SC, et al. Atrial arrhythmia after surgical closure of atrial septal defects in adults. *N Engl J Med* 1999;18:340:839–846.
- Therrien J, Gatzoulis M, Graham T, et al. Canadian Cardiovascular Society Consensus Conference 2001 update: Recommendations for the management of adults with congenital heart disease- Part 1. *Can J Cardiol* 2001;17:940–959.
- Sigler M, Jux C. Biocompatibility of septal defect closure devices. *Heart* 2007;93:444–449.
- Bruch L, Winkelmann A, Sonntag S, et al. Fenestrated occluders for treatment of ASD in elderly patients with pulmonary hypertension and/or right heart failure. *J Interv Cardiol* 2008;21:44–49. Epub 2007 Dec 11.
- Kreutzer J, Ryan CA, Gauvreau K, et al. Healing response to the Clamshell device for closure of intracardiac defects in humans. *Catheter Cardiovasc Interv* 2001;54:101–111.
- Krizanic F, Sigler M, Figulla HR. Transvenous closure of patent foramen ovale: Preliminary results with a new self-expanding nitinol wire mesh in a swine model. *Cardiol Res Pract* 2009; Epub Sep 9.
- Masura J, Gavora P, and Podnar T. Long-term outcome of transcatheter secundum-type atrial septal defect closure using Amplatzer septal occluders. *J Am Coll Cardiol* 2005;45:505–507.
- Recto MR, Sobczyk W, Hadley T, Yeh T Jr. Left atrial thrombus formation on a CardioSeal Septal Occlusion device in a patient with elevated factor VIII: Resolution with medical therapy. *J Invasive Cardiol* 2003;15:594–596.
- King TD, Mills NL. Nonoperative closure of atrial septal defects. *Surgery* 1974;75:383–388.
- King TD, Tompson SL, Steiner C, et al. Secundum atrial septal defect: Nonoperative closure during cardiac catheterization. *JAMA* 1976;235:2506–2509.
- Rashkind WJ. Experimental transvenous closure of atrial and ventricular septal defects. *Circulation* 1975;52:II-8.
- Bridges ND, Hellenbrand W, Latson L, et al. Transcatheter closure of patent foramen ovale after presumed paradoxical embolism. *Circulation* 1992;86:1902–1908.
- Halabi A, Hijazi ZM. A new device to close secundum atrial septal defects: First clinical use to close multiple defects in a child. *Catheter Cardiovasc Interv* 2008;71:853–856.